iMed

SciEPublish

Article

Simultaneous Bilateral Thalamic Hemorrhages: A Case Report and a Systematic Review of Case Reports

Matteo Fabris *, Daniele Orso, Teresa Dogareschi, Ewa Maria Bialecka and Flavio Bassi

Department of Emergency, "Santa Maria della Misericordia" University Hospital of Udine, Azienda Sanitaria Universitaria Friuli Centrale, 33100 Udine, Italy; daniele.orso@asufc.sanita.fvg.it (D.O.); teresa.dogareschi@asufc.sanita.fvg.it (T.D.); ewamaria.bialecka@asufc.sanita.fvg.it (E.M.B.); flavio.bassi@asufc.sanita.fvg.it (F.B.)

* Corresponding author. E-mail: matteo.fabris@asufc.sanita.fvg.it (M.F.)

Received: 28 July 2026; Revised: 18 September 2026; Accepted: 10 November 2026; Available online: 23 November 2026

ABSTRACT: The thalamus represents an uncommon site for intracerebral hemorrhage development. Hematomas affecting both thalami simultaneously are even rarer. This study aims to identify the leading causes of simultaneous bilateral thalamic hemorrhages, describe the main clinical manifestations of the disease, and investigate the most frequent neurological outcomes. We conducted a systematic review of the literature, including studies reporting simultaneous bilateral thalamic bleeding with hematomas strictly limited to the thalamic regions. The final analysis included 15 studies, with a pooled population of 18 patients. In-hospital mortality was 22.2%. A specific neurological assessment was available for 12 of the 14 patients discharged from the hospital: eight of these 12 patients (66.7%) showed a poor neurological outcome. The main clinical manifestations were consciousness alterations and motor impairment, whereas hypertension and coagulopathy represented the leading causes of the disease. Simultaneous bilateral thalamic hemorrhages are burdened by a high in-hospital mortality and neurological morbidity, and thus represent a condition with a substantial impact on healthcare systems. Variants of thalamic arterial vascularization (namely, the presence of the artery of Percheron) might represent the peculiar anatomical bases on which hypertension and coagulation disorders are superimposed. This literature review was registered on PROSPERO: international prospective register of Systematic Reviews, 2025, CRD42025649319 (available from: https://www.crd.york.ac.uk/prospero/display_record.php?RecordID=649319, accessed on 18 February 2025).

Keywords: Artery of Percheron; Intracerebral bleeding; Simultaneous bilateral thalamic hemorrhage; Stroke; Thalamus

1. Introduction

The thalamus is a deep diencephalic structure that acts as a relay center between the cerebral cortex and the ascending pathways from the brainstem, the spinal cord, and the cerebellum [1]. It comprises eight major nuclear groups involved in regulating movement, tactile sensitivity, specific senses (taste, sight, and hearing), balance, proprioception, consciousness, arousal, and emotions [1] (Table S1 and Figure 1A).

© 2026 The authors. This is an open access article under the Creative Commons Attribution 4.0 International License (https://creativecommons.org/licenses/by/4.0/).

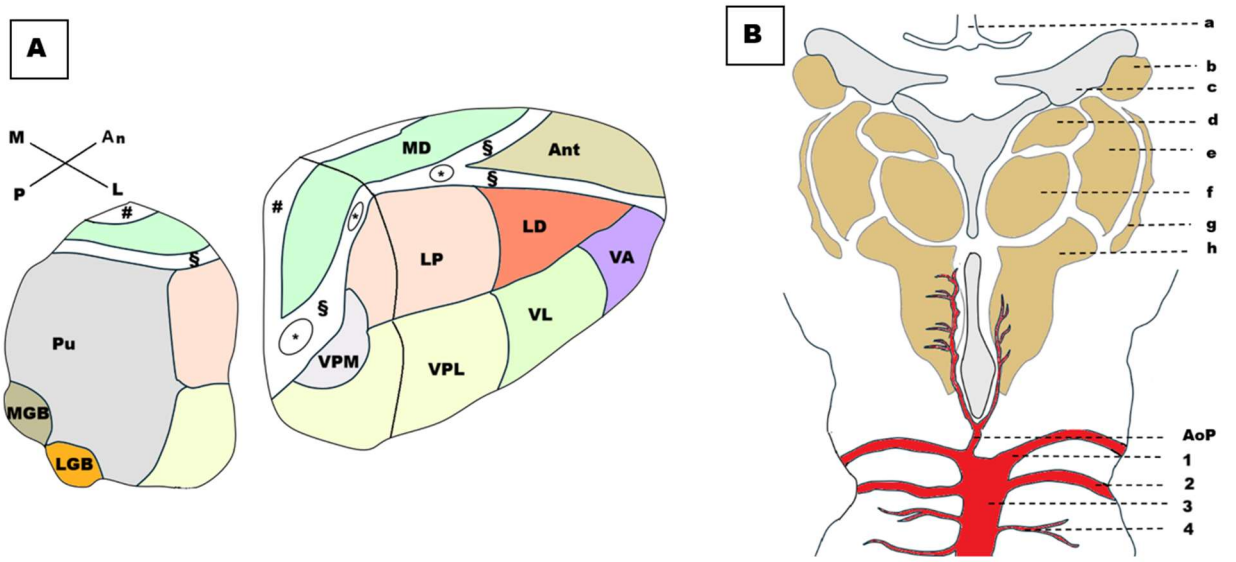

Figure 1. Schematic representations: (**A**) thalamic nuclei; (**B**) thalamic nuclei (coronal section) and variant arterial blood supply. Legend: (1) posterior cerebral artery; (2) superior cerebellar artery; (3) basilar artery; (4) pontine arteries; (AoP) artery of Percheron; (M) medial; (L) lateral; (An) anterior; (P) posterior; (a) subarachnoid space; (b) nucleus caudatus; (c) ventricular system; (d) anterior thalamic nuclei (section); (e) ventral lateral thalamic nuclei (section); (f) mediodorsal nucleus (section); (g) reticular thalamic nucleus (section); (h) ventral thalamic nuclei (section); (MGB) medial geniculate body; (LGB) lateral geniculate body; (Pu) putamen; (VPM) ventral posteromedial; (VL) ventral lateral; (VPL) ventral posterolateral; (LP) lateral posterior; (LD) dorsal lateral; (Ant) anterior; (VA) anteroventral; (MD) mediodorsal); (*) intralaminar nuclei; (§) inner medullary lamina; (#) midline nuclei.

Thalamic vascularization is provided, bilaterally, by the branches of the posterior cerebral arteries and the posterior communicating artery; in 4–12% of the population, thalamic blood supply is provided by the Artery of Percheron (AoP), an inconstant single trunk originating from the posterior cerebral artery, which supplies both thalami's arterial vascularization (Figure 1B) [2]. AoP acute occlusion has been proven to be a possible cause of acute ischemic bilateral thalamic strokes [3].

Hemorrhagic strokes account for 10–20% of all causes of strokes, with an in-hospital mortality rate of 17.9% [4,5]. Bleeding specifically affects the thalamus in 8.3–15% of intracranial hemorrhages [4,6]. Retrospective studies have shown that unilateral thalamic hematomas lead to an in-hospital mortality rate of 11%, and that 56% of patients discharged from hospital showed a good neurological outcome [7].

The aim of this review was to: (i) identify the leading causes of simultaneous bilateral thalamic hemorrhages (SBTH); (ii) verify the main clinical manifestations of the disease; (iii) recognize any suggestive manifestations or symptom associations that could arise an early clinical suspicion; (iv) investigate the most frequent neurological outcomes.

2. Case Report

A favorable assessment was obtained from the local Internal Review Board prior to the publication of this case report.

An 85-year-old male accessed the emergency department by ambulance complaining of left hemiparesis and paresthesia on the left side of his face.

His past medical history included hypertension, obesity, hypercholesterolemia, multidistrict vasculopathy with Leriche syndrome, osteoporosis, hyperparathyroidism, and smoking.

Upon the initial medical evaluation, he was eupneic, alert, oriented, and cooperative, with a Glasgow Coma Scale (GCS) score of 15. During the evaluation, he experienced a single episode of clonic seizures with urinary incontinence that lasted less than one minute and resolved spontaneously. Later, he became

drowsy and dysarthric, and his GCS score dropped to 10 (Eye 2, Verbal 3, Motor 5). Left arm became plegic. Pupils were isochoric, isocyclic and reactive to light, but a novel onset of downward gaze palsy was identified. Periodic breathing was detected as well. A concomitant hypertensive peak (202/105 mmHg) was treated with urapidil 50 mg intravenously in fractionated boluses.

CT brain scan showed bilateral thalamic hemorrhages, of approximately 3 mL each, with an almost mirror-like appearance (Figure 2A–C). No significant mass effect on the ventricular system or midline shift was detected.

The patient was subsequently intubated based on neurological criteria, and transferred to the intensive care unit (ICU). During ICU hospitalization, aggressive anti-hypertensive therapy with urapidil, doxazosin, amlodipine, ramipril, and bisoprolol was necessary. Following the discontinuation of sedation, the patient showed quadriplegia. Subsequent CT scans, performed on the second and fifth day after admission (Figure 2D–I), showed no improvement in the hematomas and were substantially unchanged compared with the initial CT scan.

The patient died on the eighth day after hospital admission. The diagnosis was bilateral thalamic hemorrhage due to uncontrolled hypertension.

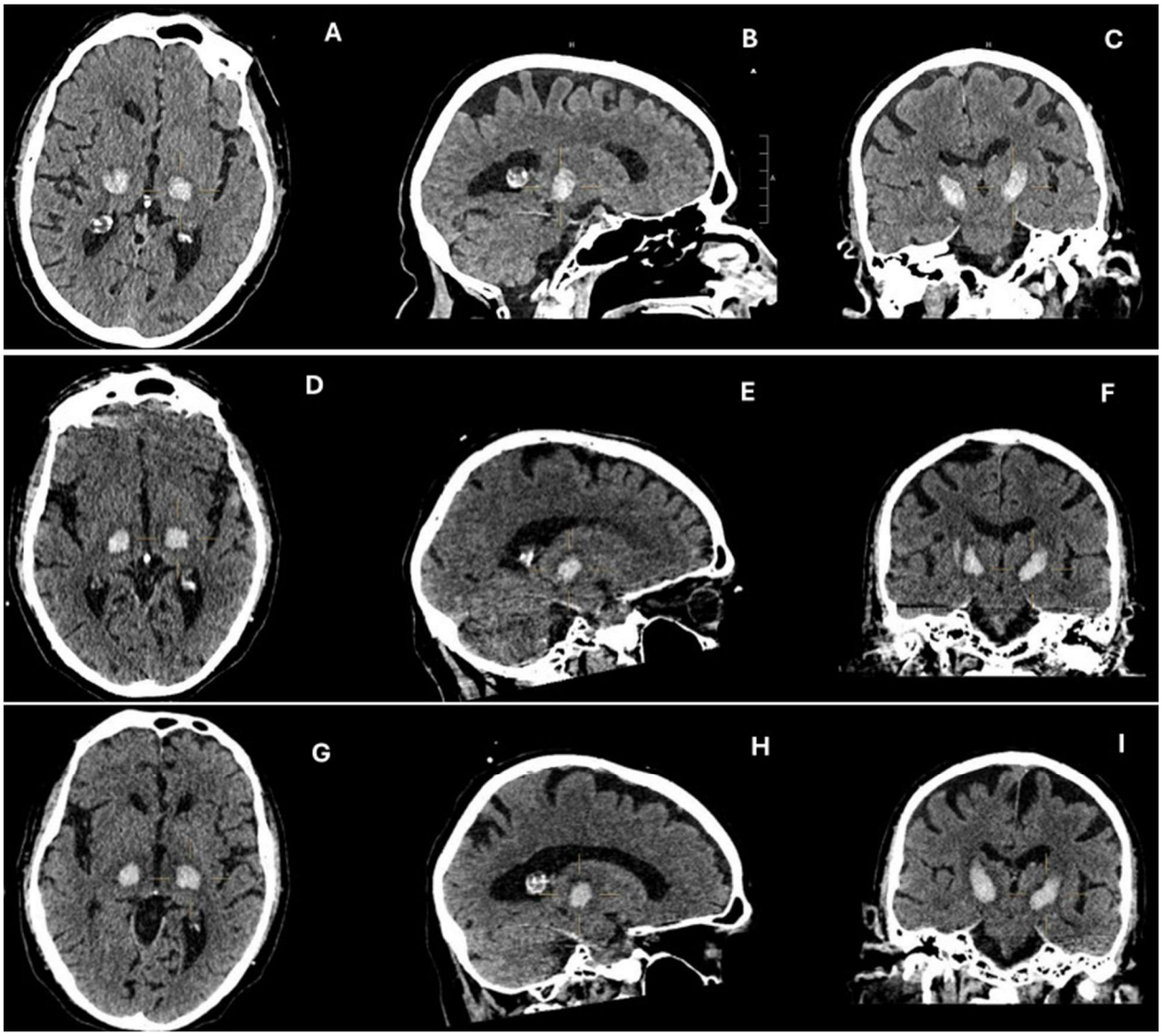

Figure 2. Consecutive computed tomography scans. Transversal (**A**,**D**,**G**), sagittal (**B**,**E**,**H**) and coronal (**C**,**F**,**I**) plans showing bilateral thalamic hemorrhages of 15 × 15 × 27 mm (left side) and 18 × 14 × 26 mm (right side). (**A**–**C**): scans completed upon the patient's entry into the hospital, showing ground-like intraparenchymal blood collection in the thalamic area, bilaterally, with

an almost mirror-like appearance. The most caudal sectors of the blood extravasation partially involve the cerebral peduncles. Both blood collections are surrounded by a hypodense halo. There is no significant mass effect on the ventricular system or midline shift. (**D**–**F**): control scans at 48 h; no further changes. (**G**–**I**): control scans at 5 days; no further substantial modifications.

3. Materials and Methods

Through an extensive systematic review of the literature, we gathered all case reports and studies related to SBTH (Table S2).

Suitability of the studies to be included in our review was double-checked relying on both the paper's description of the patients and the attached figures.

This literature review was registered on PROSPERO: International Prospective Register of Systematic Reviews, 2025, CRD42025649319 (available from: https://www.crd.york.ac.uk/prospero/display_record.php?RecordID=649319, accessed on 18 February 2025).

3.1. Data Extraction

Two independent authors (M.F. and D.O.) searched five databases for relevant articles: PubMed, Scopus, Google Scholar, SpringerLink, and Elsevier ScienceDirect. The full search strategy is outlined in Data S1. All articles matching the research criteria were collected, and their full texts were retrieved. Further, the reference list of the included papers was manually searched to identify any additional relevant studies.

After full-text review, articles that did not meet the Critical Appraisal Skills Program (CASP) criteria (such as relevance to the review aim) were excluded from further analysis [8].

3.2. Inclusion Criteria

Given the rarity of the studied phenomena, we used broad criteria for article selection. We included interventional studies, observational studies, case reports, and case series that referred to SBTH. Whenever feasible, we extracted single-case reports or patient descriptions from interventional/observational studies that would otherwise have been excluded.

Only articles that specifically mentioned clinical manifestations, imaging findings, neurological outcomes, and the leading cause of the disease were taken into account.

We considered CT and MRI parenchymal brain scans suitable for assessing hematoma site and extension. Papers reporting venography and angiography findings were included as well.

We retrieved studies involving adult patients exclusively (age ≥ 18 years).

3.3. Exclusion Criteria

Articles published in foreign languages were excluded if attempts to translate into English were unsuccessful (Data S1).

Guidelines, policy statements, research protocols, and studies involving preclinical research or non-human patients were also not included.

Articles describing subsequent bilateral thalamic hemorrhages, ischemic thalamic strokes, or detailing isolated hematomas located other than the thalami were excluded. SBTH that developed in association with other intracerebral bleedings were not included either. Post-traumatic hemorrhages and hemorrhagic transformation of venous infarcts were not considered.

The index case we described was excluded from the systematic review.

3.4. Quality Appraisal

Given the rarity of the studied phenomena, the whole literature consisted of case reports or individual cases excerpted from interventional studies, observational studies, or case series.

A modified version of the Joanna Briggs Institute (JBI) checklist for case reports was used to evaluate both the quality of case reports and extracted individual cases [9] (Data S1). Even within the same study, the descriptions of patients may be heterogeneous in terms of quality, amount, or comprehensiveness of the information provided. Thus, the bias risk may differ accordingly. Therefore, we used the JBI tool to independently assess the risk of bias for each single case presented, whether it was drawn from the literature as a case report or excerpted from interventional/observational studies or case series.

We distinguished the included cases as "low", "moderate" or "high" risk of bias. For all included cases, we answered each question of the JBI checklist with "yes", "unclear" or "no", according to the report description. The bias risk was thus assessed as follows:

- 1 "unclear" answer alone: low risk;
- 2 "unclear" answers: moderate risk;
- 3 "unclear" answers: high risk;
- 1 "no" answer alone: moderate risk;
- 1 "no" answer + ≥1 "unclear" answers: high risk;
- ≥2 "no" answers: high risk.

Two independent authors (M.F. and D.O.) used the JBI tool to assess the methodological quality of the cases provided. For any disagreement between the two reviewers, a third author (TD) was involved. Agreement among two of three authors was considered sufficient to include the case in the systematic review.

3.5. Synthesis of Data

We collected the following data for each study included in the review: study type, age, sex, signs and symptoms, Glasgow Coma Scale (GCS) at admission, arterial blood pressure at first medical evaluation, medical history, further clinical or laboratory findings, imaging data, suspected etiology, therapy, and neurological outcome (Table 1).

Given the heterogeneous description provided by the different papers, outcomes were categorized into three categories: "optimal" referred to patients discharged from hospital without any cognitive, sensitive or motor deficit; "good" was used to describe subjects with slight neurological impairments (e.g., corresponding to a modified Rankin scale score of 1 or 2); "poor" accounted for patients discharged with moderate to severe neurological deficits (e.g., requiring assistance to walk or perform activities of daily living).

Table 1. List of the studies included in the systematic review and their characteristics.

n	References	Study Type	Sex	Age (Years)	Blood Pressure (mmHg)	Other Findings	Comorbidities	Leading Cause	Therapy
1	Vallejos C. et al., 2006 (case 1) [10]	CS	F	58	210/100	INR 2.8	Smoker. Hypertension. Atrial fibrillation. Acenocumarol therapy. Dyslipidemia.	Hypertension + anticoagulation	Fresh frozen plasma + K vitamin
2	Yen C. P. et al., 2004 (case 3) [11]	RS	M	63	nd	nd	Hypertension	Hypertension	Medical
3	Yen C. P. et al., 2004 (case 7) [11]	RS	M	69	nd	nd	Hypertension	Hypertension	Medical
4	Yen C. P. et al., 2004 (case 8) [11]	RS	F	68	nd	nd	Hypertension	Hypertension	Medical
5	Takeuchi S. et al., 2011 (case 12) [12]	RS	M	68	201/82	nd	Hypertension. Alcoholism.	Hypertension.	nd
6	Takeuchi S. et al., 2011 (case 18) [12]	RS	F	73	269/123	nd	Hypertension. Renal failure.	Hypertension.	nd
7	Ghoreishi A. et al., 2021 [13]	CR	F	57	160/90	None	Hypertension. Previous cerebrovascular accident	Hypertension.	Antihypertensive drugs
8	Al-Shahwani Z. A. et al., 2024 [14]	CR	M	67	170/80	None	Smoker. Ischemic heart disease.	Hypertension	Antihypertensive drugs
9	Dromerick A. W. et al., 1997 [15]	CR	F	73	nd	t-PA 100 mg iv administration 24 h before due to acute myocardial infraction.	nd	Anticoagulation	nd
10	Imai K. 2000 [16]	CR	M	54	230/120	None	nd	Hypertension	Antihypertensive drugs
11	Malandrini A. et al., 2004 [17]	CR	M	41	nd	Right pneumonia. Acute myocarditis.	Rheumatic polymyalgia.	Suspected infection	nd
12	Turkar A. et al., 2021 [18]	CR	M	65	nd	nd	COVID-19 infection.	Suspected infection	nd
13	Rezende M. T. et al., 2006 [19]	CR	M	66	nd	Endovascular stenting + anticoagulation with heparin completed 24h prior the event	Previous posterior inferior cerebellar artery occlusion treated	Hemorrhage secondary to hyperperfusion syndrome	Antihypertensive drugs + heparin discontinuation + DAPT introduction
14	Choudhary A. et al., 2018 [20]	CR	M	54	180/100	nd	Smoker. Alcohol consumer.	Hypertension.	Medical

15	Brenner A. et al., 2021 [21]	CR	F	53	210/110	nd	nd	Hypertension	Antihypertensive drugs
16	Ng Y. S. et al., 2013 [22]	CR	M	61	nd	Venous hypertension due to vein of Galen dural arteriovenous fistula	nd	Intracranial arteriovenous fistula	Heparin + embolization
17	Vandenborre D. et al., 2015 [23]	CR	M	22	nd	Neurosurgery post-operative period	Previous 5 neurosurgery operations and radiotherapy due to recurrent brain glioma	Possible surgery complication	nd
18	Schachter D. et al., 2025 [24]	CR	M	67	166/94	Cocaine assumption	Hypertension. Diabetes	Hypertension	nd

Abbreviations: (RS) retrospective study; (CR) case report; (CS) case series; (nd) data not described by the author; (none) no further data described into the report that are relevant for the aim of this review; (DAPT) dual antiplatelet therapy; (t-PA) tissue plasminogen activator; (F) female; (M) male.

3.6. Statistical Analysis

Statistical analysis was performed using the R Project for Statistical Computing, version 4.4.0 (R Core Team [2024]. R Foundation for Statistical Computing, Vienna, Austria. URL: https://www.r-project.org/, accessed on 28 February 2026).

Mean and standard deviation were used to summarize continuous variables. Categorical variables were expressed as absolute values, frequencies, and percentages.

Further statistical analyses were not performed, as the limited sample size would have made quantitative inference unreliable.

4. Results

PRISMA flowchart selection for studies is shown in Figure 3 [25].

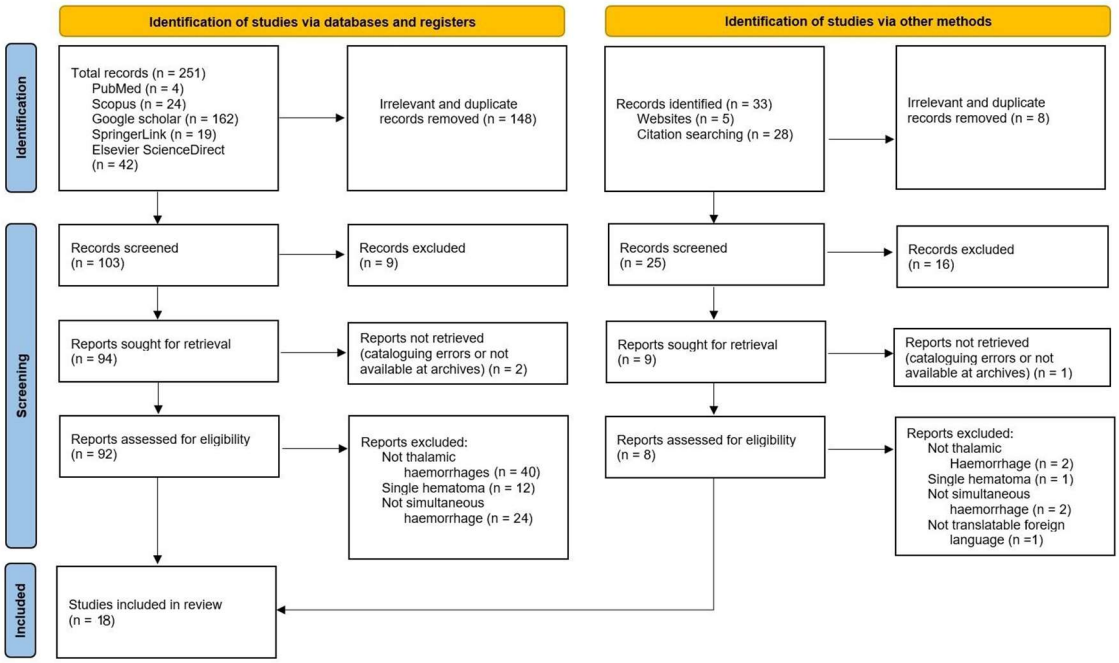

Figure 3. PRISMA flow-chart for studies selection.

Our literature research found 284 papers. After abstract evaluation and duplicates removal, 103 articles were sought for full-text retrieval. Fifteen studies were selected: one case series ([10]), two retrospective studies ([11,12]) and 12 case reports ([13–24]).

Given the restrictive research parameters, not all the patients described in the case series and retrospective studies matched our review's inclusion criteria; specific population subgroups were thus extracted from these studies: one patient description was obtained from the case series and five patients descriptions were selected from retrospective studies. After such an elaboration, the review consisted of 18 single-patient descriptions, with 12 (66.7%) males and six (33.3%) females (Table S3). The mean age was 59.9 ± 12.1 years.

4.1. Quality Appraisal

According to JBI checklist evaluation, a low risk of bias was detected in five (27.8%) cases ([10,13,16,19,22]); three cases (16.7%) showed a moderate risk for bias ([20,23,24]), whereas 10 cases (55.6%) showed a high risk ([11,12,14,15,17,18,21]) (Table 2).

Failing to describe additional signs and symptoms presented by the patient was the primary factor contributing to an increased risk of bias. Insufficiently detailed past medical history and therapy were influent as well.

Table 2. Critical appraisal of the selected studies according to the JBI modified checklist.

n	Reference	Were the Patient's Demographic Characteristics Clearly Described?	Was the Patient's History Clearly Described and Presented as a Timeline?	Was the Current Clinical Condition of the Patient on Presentation Clearly Described?	Were Diagnostic Tests or Assessment Methods and the Results Clearly Described?	Were the Intervention(s) or Treatment Procedure(s) Clearly Described?	Was the Post-Intervention Clinical Condition Clearly Described?	Bias Risk
1	Vallejos C. et al., 2006 (case 1) [10]	Yes	Yes	Yes	Yes	Yes	Yes	Low
2	Yen C. P. et al., 2004 (case 3) [11]	Yes	Unclear	Unclear	Unclear	Unclear	Yes	High
3	Yen C. P. et al., 2004 (case 7) [11]	Yes	Unclear	Unclear	Unclear	Unclear	Yes	High
4	Yen C. P. et al., 2004 (case 8) [11]	Yes	Unclear	Unclear	Unclear	Unclear	Yes	High
5	Takeuchi S. et al., 2011 (case 12) [12]	Yes	Unclear	Unclear	Unclear	No	Yes	High
6	Takeuchi S. et al., 2011 (case 18) [12]	Yes	Unclear	Unclear	Unclear	No	Yes	High
7	Ghoreishi A. et al., 2021 [13]	Yes	Yes	Yes	Yes	Yes	Yes	Low
8	Al-Shahwani Z. A. et al., 2024 [14]	Yes	Yes	Yes	Unclear	Yes	No	High
9	Dromerick A. W. et al., 1997 [15]	Yes	Unclear	Yes	Unclear	No	Yes	High
10	Imai K. 2000 [16]	Yes	Unclear	Yes	Yes	Yes	Yes	Low
11	Malandrini A. et al., 2004 [17]	Yes	Yes	Unclear	Unclear	No	Yes	High
12	Turkar A. et al., 2021 [18]	Yes	Unclear	Unclear	Unclear	No	Yes	High
13	Rezende M. T. et al., 2006 [19]	Yes	Yes	Yes	Unclear	Yes	Yes	Low
14	Choudhary A. et al., 2018 [20]	Yes	Unclear	Yes	Yes	Unclear	Yes	Moderate
15	Brenner A. et al., 2021 [21]	Yes	No	Yes	Unclear	Yes	No	High
16	Ng Y. S. et al., 2013 [22]	Yes	Unclear	Yes	Yes	Yes	Yes	Low
17	Vandenborre d. et al., 2015 [23]	Yes	Yes	Yes	Yes	No	Yes	Moderate
18	Schachter D. et al., 2025 [24]	Yes	Yes	Yes	Yes	No	Yes	Moderate

4.2. Outcomes

In-hospital mortality was 22.2%. Fourteen patients (77.8%) were discharged from hospital; for 12 of them, studies granted for a specific evaluation of neurological residual impairment at hospital discharge: two of 12 patients (16.7%) showed an "optimal" outcome, two of 12 subjects (16.7%) were discharged with a "good" neurological status, whereas eight of 12 patients (66.7%) were referred to the "poor" subgroup (Tables S3 and S4).

4.3. Causes

Uncontrolled arterial blood pressure was the main cause of SBTH. A hypertensive peak was detected in 11 patients (61.1%); among this specific subgroup, nine subjects (81.8%) chronically suffered from hypertension. The mean systolic and diastolic blood pressures were, of 199.6 ± 33.2 mmHg (95% CI: [177.9–221.3]) and 99.9 ± 14.5 mmHg (95% CI: [90.4–109.3]), respectively.

Other potential causes of SBTH included infection (11.1%), coagulopathy (5.6%), hyperperfusion syndrome (5.6%), intracranial arteriovenous fistula (5.6%), surgical complications (5.6%), and an overlap between hypertension and coagulopathy (5.6%) (Figure 4A and Table S3).

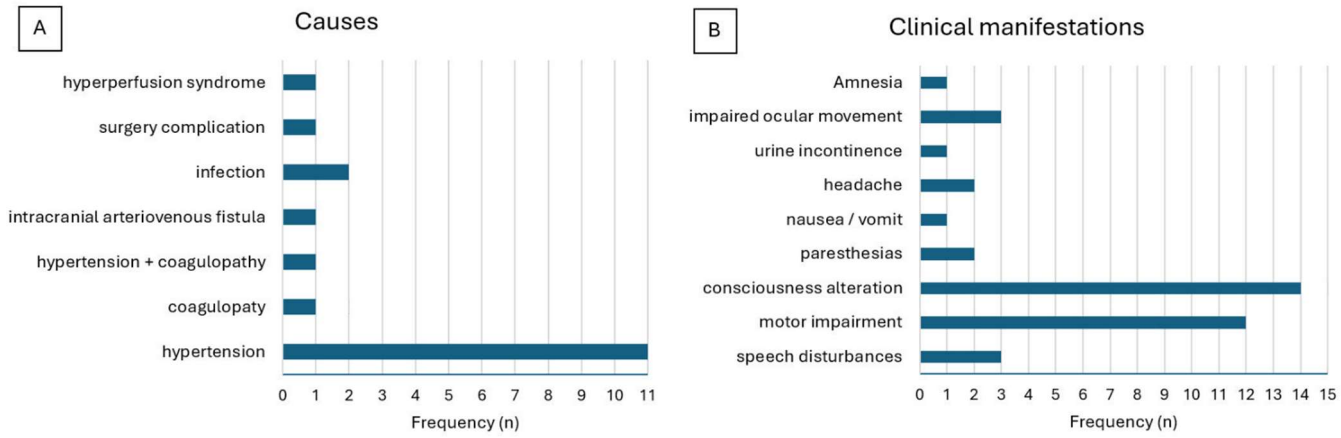

Figure 4. Histograms representing the causes (**A**) and clinical presentations (**B**) of SBTH.

4.4. Signs and Symptoms

Consciousness alterations (drowsiness or GCS reduction) represented the main finding at the initial medical evaluation (77.8%). Other common presentations were motor impairment (hemiparesis, hemiplegia, or quadriplegia: 66.7%), speech disturbances (16.7%), and impaired ocular movements (skew deviation or gaze palsy: 16.7%) (Figure 4B, Tables S3 and S4).

Six studies were granted for a GCS evaluation upon patient admission; the average score was 9.2 ± 3.4 (95% CI: [5.7–12.6]).

4.5. Imaging Techniques

CT was the preferred diagnostic technique (72.2% of cases), whereas MRI represented the exam of choice during the follow-up (22.2%). Further radiological exams used during follow-up included angiography (5.6%), MRI venography (5.6%), and single-photon emission computed tomography (5.6%) (Tables S3 and S4).

5. Discussion

Stroke is an acute, persistent neurological deficit affecting the brain, retina, or spinal cord, due to ischemia or bleeding [26]. Hemorrhagic subtypes represent 10% to 20% of all strokes and could be further classified into non-traumatic intracerebral hemorrhages (ICH) and subarachnoid hemorrhages [27,28].

Potential causes of hemorrhagic strokes include hypertension, cerebral amyloid angiopathy, vascular abnormalities (such as arteriovenous malformation and aneurysms), coagulopathy, thrombocytopenia, anticoagulant drugs, and cerebral malignancies [27,29,30].

ICH most commonly affects the basal ganglia (particularly the putamen) and the subcortical areas of the cerebral lobes [4,31,32]. The cerebellum, pons, brain stem, and ventricular system are less common sites [4,27–30]. The thalamus is involved in 8.3–15% of all ICH cases, making it an atypical location [4,6,33].

The brain structure damaged in ICH depends on the vessel primarily injured. The lenticulostriate arteries (LSA), which are branches of the middle cerebral artery (MCA), are the vessels most frequently damaged; LSA ensures blood supply to the putamen and the globus pallidus, thus explaining the high frequency of basal ganglia involvement [32].

The pathogenesis of ICH in "typical sites" usually involves the geometric features of the MCA, such as its proximal to distal diameter and curvature angle over the proximal tract [34]. Abnormalities in these characteristics have been found to increase shear stress, allowing blood flow to exert excessive forces on the endothelium [35]. The combination of these features, coupled with chronic blood hypertension, might lead to the formation of Charcot-Bouchard microaneurysm in the MCA or LSA, thus predisposing to rupture and consequent ICH [36,37].

The whole thalamus vascularization is supplied by blood vessels originating from the posterior cerebral arteries (the thalamogeniculate artery and the posterior choroidal arteries) and the posterior communicating arteries (the tuberothalamic artery) [38]. Despite its specific vascularization, ICHs primarily originating from thalamus and strictly confined within its borders are very rare; most of them extend towards the ventricular system, the inner capsule, or the basal ganglia [39]. These findings could be explained by pathogenic mechanisms common to both intracerebral hemorrhage (ICH) and isolated thalamic bleeding. Lee et al. showed how, similarly to ICH in general, hypertension and coagulation impairment were the main predisposing factors for isolated unilateral thalamic hemorrhages [7].

SBTH are even rarer, and almost anecdotal; according to our literature review, only 18 cases had previously been described. The most frequent morbidity suffered by the patients included in our study was hypertension (61.1% of the total population). Infection was found to be a possible cause of SBTH as well (11.1% of the population). In 5.6% of cases, an overlap between hypertension and coagulation disturbances was observed, suggesting that, even in SBTH, a coagulation impairment might exacerbate blood vessels fragility driven by hypertension.

The reason why hypertension could lead to ICHs strictly confined to both thalami, without any further brain structure impairment, remains unclear. One possible hypothesis concerns anomalous thalamic vascularization. In 4–12% of the population, thalamic bilateral blood supply is provided by the AoP, an inconstant single trunk that originates from the posterior cerebral artery (Figure 1B) [1,2]. AoP acute occlusion has been proven to be a possible cause of acute ischemic bilateral thalamic strokes [3]. Theoretically, a lesion of the AoP may lead to SBTH as well; according to this hypothesis, the pathogenic mechanism could potentially mimic the Charcot-Bouchard microaneurysm formation in the MCA or the LSA (arterial geometric alterations, shear stress, and hypertension-driven weakening of the vascular layers). We therefore hypothesize that an anomalous blood supply to the thalami, provided by the AoP, may constitute a potential predisposing factor for SBTH.

Retrospective studies have shown that unilateral thalamic hematomas lead to an in-hospital mortality of 11%, while patients discharged from hospital showed a good neurological outcome in 56% of cases [7].

Conversely, according to the results of our review, SBTH are associated with an in-hospital mortality of 22.2%; furthermore, a good neurological outcome was observed in only 33.3% of cases (specifically, in four of the 12 patients for whom the neurological status at hospital discharge was reported).

Given the high mortality and morbidity associated with SBTH, an early clinical suspicion is essential. Due to the vast amount of functions performed by the thalamus, clinical manifestations may refer to a wide variety of signs and symptoms, depending on the nuclei involved (Table S1 and Figure 1A). According to the results of our review, the most common clinical manifestations are (in decreasing order of frequency): consciousness reduction, motor alterations (hemiparesis, hemiplegia, or quadriplegia), ocular movements impairment (skew deviation, or gaze palsy), speech disturbances (dysarthria, or aphasia), nausea/vomiting, and urine incontinence.

5.1. Conclusions

Based on the results of our review, SBTHs appear to be burdened by a high in-hospital mortality (22.2%) and morbidity; our literature review indicates that a poor neurological outcome at hospital discharge is observed in 66.7% of cases (eight of 12 patients). Despite their rarity (only 18 cases identified in our literature review), SBTH might nonetheless represent a pathology with a major impact on healthcare systems and, potentially, of great interest to clinicians.

5.2. Limitations

Given the rarity of the studied phenomena, the review included an exiguous number of patients, which makes it unfeasible to establish robust inferences about the general population. Further, the whole population was extracted from case reports, which are known to be inherently prone to bias. Moreover, critical appraisal detected a low risk of bias in only a minority of cases (27.8%).

Due to the heterogeneity of the cases' descriptions, it was not possible to categorize the patients' outcomes based on a uniform, validated neurological measure. Therefore, the classification of neurological outcomes at discharge into the three categories of "optimal", "good", and "poor" may have introduced a classification bias.

Although the anatomical and pathophysiological bases might suggest so, an AoP lesion as a potential cause of SBTH remains a theoretical hypothesis; none of the cases provided in this review have identified a causal relationship between these two events. An AoP injury would require a CT angiography or an MRI angiography to be unequivocally identified. These imaging techniques are not routinely performed for ICH identification and, when required, scans are more likely to explore the intracerebral vascularization (namely the circle of Willis), excluding the mesencephalic sections, where the AoP arises (Figure 1B). When a direct-access head CT scan shows SBTH, scan sections might be extended to the mesencephalic area, in order to detect an AoP impairment.

Supplementary Materials

The following supporting information can be found at: https://www.sciepublish.com/article/pii/1342, Table S1: Thalamic nuclei and their functions; Table S2: PRISMA checklist; Table S3: Characteristics of the population included; Table S4: Neurological evaluation, imaging findings, and neurological outcomes of the patients included in the systematic review; Data S1: Articles retrieval and bias risk assessment procedures.

Statement of the Use of Generative AI and AI-Assisted Technologies in the Writing Process

During the preparation of this manuscript, the authors used ChatGPT (GPT-6, OpenAI), in order to check spelling and grammar. After using this tool, the authors reviewed and edited the content as needed and take full responsibility for the content of the published article.

Author Contributions

Conceptualization: M.F.; methodology: M.F. and D.O.; software: M.F. and D.O.; validation: M.F.; formal analysis: M.F. and D.O.; investigation: M.F., D.O. and T.D.; resources: M.F., F.B. and E.M.B.; data curation: M.F. and D.O.; writing-original draft preparation: M.F.; writing-review and editing: M.F. and D.O.; visualization: M.F.; supervision: T.D. and F.B. All authors have read and agreed to the published version of the manuscript.

Ethics Statement

Not applicable.

Informed Consent Statement

A favorable assessment was obtained from the local Internal Review Board prior to the publication of the case report (protocol number 126/2025). Consent for publication from the patient was waived by the local IRB.

Data Availability Statement

All data generated or analyzed during this study are included in this published article.

Funding

The authors did not receive support from any organization for the submitted work.

Declaration of Competing Interest

The authors have no conflicts of interest to declare that are relevant to the content of this article.

References

1. Torrico TJ, Munakomi S. Neuroanatomy, Thalamus. In *StatPearls*; StatPearls Publishing: Treasure Island, FL, USA, 2025.
2. Atallah O, Almealawy YF, Alabide AS, Farooq M, Sanker V, Alrubaye SN, et al. Navigating the clinical landscape of artery of Percheron infarction: A systematic review. *eNeurologicalSci* **2024**, *37*, 100521. DOI:10.1016/j.ensci.2024.100521
3. Phate N, Pawar T, Andhale A, Kumar Singh R, Talwar D, Acharya S, et al. Artery of Percheron Stroke: A Case Report With a Diagnostic Challenge. *Cureus* **2022**, *14*, e21939. DOI:10.7759/cureus.21939
4. Chen S, Zeng L, Hu Z. Progressing haemorrhagic stroke: Categories, causes, mechanisms and managements. *J. Neurol.* **2014**, *261*, 2061–2078. DOI:10.1007/s00415-014-7291-1
5. Kelly DM, Feld J, Rothwell PM, Reinecke H, Koeppe J. Admission Rates, Time Trends, Risk Factors, and Outcomes of Ischemic and Hemorrhagic Stroke from German Nationwide Data. *Neurology* **2022**, *99*, e2593–e2604. DOI:10.1212/WNL.0000000000201259
6. Hu YZ, Wang JW, Luo BY. Epidemiological and clinical characteristics of 266 cases of intracerebral hemorrhage in Hangzhou, China. *J. Zhejiang Univ. Sci. B* **2013**, *14*, 496–504. DOI:10.1631/jzus.B1200332
7. Lee SH, Park KJ, Kang SH, Jung YG, Park JY, Park DH. Prognostic Factors of Clinical Outcomes in Patients with Spontaneous Thalamic Hemorrhage. *Med. Sci. Monit.* **2015**, *21*, 2638–2646. DOI:10.12659/MSM.894132
8. Critical Appraisal Skills Programme. CASP (Systematic Review) Checklist. 2018. Available online: https://casp-uk.net/casp-tools-checklists/ (accessed on 1 February 2025).
9. Aromataris E, Lockwood C, Porritt K, Pilla B, Jordan Z. (Eds.). *JBI Manual for Evidence Synthesis*; JBI: Adelaide, South Australia, Australia, 2024. DOI:10.46658/JBIMES-24-01
10. Vallejos CJ, Mellado TP, Huete LI. Hematoma talámico bilateral simultáneo: Reporte de dos casos y revisión de la literatura. *Rev. Chil. Neuropsiquiatr.* **2006**, *44*, 127–133. DOI:10.4067/S0717-92272006000200005
11. Yen CP, Lin CL, Kwan AL, Lieu AS, Hwang SL, Lin CN, et al. Simultaneous multiple hypertensive intracerebral haemorrhages. *Acta Neurochir.* **2005**, *147*, 393–399. DOI:10.1007/s00701-004-0433-y

12. Takeuchi S, Takasato Y, Masaoka H, Hayakawa T, Yatsushige H, Sugawara T. Simultaneous multiple hypertensive intracranial hemorrhages. *J. Clin. Neurosci.* **2011**, *18*, 1215–1218. DOI:10.1016/j.jocn.2011.01.020
13. Ghoreishi A, Malekmahmoudi G, Molseghi MH, Gholizadeh M, Sabzehparvar M. A Rare Case of Simultaneous Recurrent Bilateral Hypertensive Thalamic Hemorrhage: A Rare Case Report. *Case Rep. Clin. Pract.* **2021**, *6*, 284–287. Available online: https://crcp.tums.ac.ir/index.php/crcp/article/view/471 (accessed on 9 November 2026).
14. Al-Shahwani ZA, Taha GM, Saoodi RN, Faisal M. Bilateral Spontaneous Thalamic Hemorrhage: A Case Report. *Cureus* **2024**, *16*, e67258. DOI:10.7759/cureus.67258
15. Dromerick AW, Meschia JF, Kumar A, Hanlon RE. Simultaneous bilateral thalamic hemorrhages following the administration of intravenous tissue plasminogen activator. *Arch. Phys. Med. Rehabil.* **1997**, *78*, 92–94. DOI:10.1016/S0003-9993(97)90018-6
16. Imai K. Bilateral simultaneous thalamic hemorrhages—Case report. *Neurol. Med. Chir.* **2000**, *40*, 369–371. DOI:10.2176/nmc.40.369
17. Malandrini A, Luchini D, Gambelli S, Gaudiano C, Berti G, Salvadori C, et al. A syndrome of bilateral hemorrhage of the thalamus and myocarditis with fatal course. *J. Clin. Forensic Med.* **2004**, *11*, 208–210. DOI:10.1016/j.jcfm.2004.04.009
18. Turkar A, Günbey HP. COVID-19 associated acute encephalopathy features on computed tomography: A case report. *J. Surg. Med.* **2021**, *5*, 108–110. DOI:10.28982/josam.771230
19. Rezende MT, Spelle L, Mounayer C, Piotin M, Abud DG, Moret J. Hyperperfusion syndrome after stenting for intracranial vertebral stenosis. *Stroke* **2006**, *37*, e12–e14. DOI:10.1161/01.STR.0000196959.77184.49
20. Choudhary A, Goyal MK, Singh R. Simultaneous bilateral hypertensive thalamic hemorrhage: A rare event. *Neurol. India* **2018**, *66*, 575–577. DOI:10.4103/0028-3886.227323
21. Brenner A, Cardoso A, Ries A, Ribeiro M, Worm P. A case report of a bilateral thalamic hemorrhage. *J. Neurol. Sci.* **2021**, *429*, 119722. DOI:10.1016/j.jns.2021.119722
22. Ng YS, Downer J, Keston P, Derry C. A reversible cause of bilateral thalamic infarct and cognitive impairment. *J. Neurol. Sci.* **2013**, *333*, e217. DOI:10.1016/j.jns.2013.07.860
23. Vandenborre D, Van Dun K, Mariën P. Apraxic agraphia following bithalamic damage. *Brain Cogn.* **2015**, *95*, 35–43. DOI:10.1016/j.bandc.2015.01.012
24. Schachter D, Sharma N. Abstract 313: Intracerebral Hemorrhage in Artery of Percheron Territory: A Rare Case of Bilateral Thalamic Hemorrhage. *Stroke Vasc. Interv. Neurol.* **2024**, *4*, e12984_313. DOI:10.1161/SVIN.04.suppl_1.313
25. Page MJ, McKenzie JE, Bossuyt PM, Boutron I, Hoffmann TC, Mulrow CD, et al. The PRISMA 2020 statement: An updated guideline for reporting systematic reviews. *BMJ* **2021**, *372*, n71. DOI:10.1136/bmj.n71
26. Sacco RL, Kasner SE, Broderick JP, Caplan LR, Connors JJ, Culebras A, et al. An updated definition of stroke for the 21st century: A statement for healthcare professionals from the American Heart Association/American Stroke Association. *Stroke* **2013**, *44*, 2064–2089. DOI:10.1161/STR.0b013e318296aeca
27. Unnithan AKA, Das JM, Mehta P. Hemorrhagic Stroke. In *StatPearls*; StatPearls Publishing: Treasure Island, FL, USA, 2025.
28. Tadi P, Lui F. Acute Stroke. In *StatPearls*; StatPearls Publishing: Treasure Island, FL, USA, 2025.
29. Kitagawa K. Blood pressure management for secondary stroke prevention. *Hypertens. Res.* **2022**, *45*, 936–943. DOI:10.1038/s41440-022-00908-1
30. Castello JP, Pasi M, Kubiszewski P, Abramson JR, Charidimou A, Kourkoulis C, et al. Cerebral Small Vessel Disease and Depression Among Intracerebral Hemorrhage Survivors. *Stroke* **2022**, *53*, 523–531. DOI:10.1161/STROKEAHA.121.035488
31. Rymer MM. Hemorrhagic stroke: Intracerebral hemorrhage. *Mo. Med.* **2011**, *108*, 50–54. Available online: https://pmc.ncbi.nlm.nih.gov/articles/PMC6188453/ (accessed on 9 November 2026).
32. Steiner T, Kaste M, Forsting M, Mendelow DA, Kwieciński H, Szikora I, et al. Recommendations for the management of intracranial haemorrhage—Part I: Spontaneous intracerebral haemorrhage. *Cerebrovasc. Dis.* **2006**, *22*, 294–316. DOI:10.1159/000094831
33. Arboix A, Rodríguez-Aguilar R, Oliveres M, Comes E, García-Eroles L, Massons J. Thalamic haemorrhage *vs.* internal capsule-basal ganglia haemorrhage: Clinical profile and predictors of in-hospital mortality. *BMC Neurol.* **2007**, *7*, 32. DOI:10.1186/1471-2377-7-32
34. Liu D, Zhang G, Wang Y, Li J, Cao P, Yin X, et al. Geometric features of middle cerebral artery are associated with spontaneous basal ganglia intracerebral haemorrhage. *Stroke Vasc. Neurol.* **2022**, *7*, 399–405. DOI:10.1136/svn-2021-001277
35. Friedman MH. Variability of 3D arterial geometry and dynamics, and its pathologic implications. *Biorheology* **2002**, *39*, 513–517. DOI:10.1177/0006355X2002039003004032

36. Hoi Y, Meng H, Woodward SH, Bendok BR, Hanel RA, Guterman LR, et al. Effects of arterial geometry on aneurysm growth: Three-dimensional computational fluid dynamics study. *J. Neurosurg.* **2004**, *101*, 676–681. DOI:10.3171/jns.2004.101.4.0676
37. Gupta K, Das JM. Charcot-Bouchard Aneurysm. In *StatPearls*; StatPearls Publishing: Treasure Island, FL, USA, 2025.
38. Bordes S, Werner C, Mathkour M, McCormack E, Iwanaga J, Loukas M, et al. Arterial Supply of the Thalamus: A Comprehensive Review. *World Neurosurg.* **2020**, *137*, 310–318. DOI:10.1016/j.wneu.2020.01.237
39. Piepgras U, Rieger P. Thalamic bleeding: Diagnosis, course and prognosis. *Neuroradiology* **1981**, *22*, 85–91. DOI:10.1007/BF00344779